PART 4 | Trauma

CHAPTER 28

Traumatic brain injury

Learning objectives†

To be familiar with:

- The physiology of cerebral blood flow and the pathophysiology of raised intracranial pressure
- The resuscitation, assessment, investigation and continuing care of head-injured patients
- The prevention and detection of secondary intracranial and systemic insults

INTRODUCTION

Head injury accounts for 3–4% of emergency department attendances, with around 1500 cases per 100 000 population per year in the UK. Annual mortality attributable to head injury is estimated at 9 per 100 000, and it remains the leading cause of death and disability from childhood to early middle age, with an estimated 2% of the US population suffering long-term disability as a result of head injury. Road traffic accidents are the leading cause of head injury, responsible for up to 50% of cases. Other common mechanisms of injury include falls and assault. There is significant geographical variation, for example firearms are the third leading cause in the USA.

Traumatic brain injury (TBI) can be considered as the combination of primary injury sustained on impact, and hence not medically modifiable, and secondary injury developing in the following hours and days. Understanding the importance of intracranial pressure (ICP) and related parameters is key to minimising secondary injury and improving outcomes.

INTRACRANIAL PRESSURE

Intracranial pressure and cerebral blood flow

The brain depends on continuous perfusion for oxygen and glucose delivery, and hence survival. Normal cerebral blood flow (CBF) is about 55 mL/min for every 100 g of brain tissue. Ischaemia results when this rate drops below 20 mL/min, and even lower levels will result in infarction unless promptly corrected.

Flow depends on cerebral perfusion pressure (CPP), which is the difference between the mean arterial pressure (MAP) and the intracranial pressure (ICP):

CPP (75–105 mmHg) =
MAP (90–110 mmHg) – **ICP** (5–15 mmHg)

Typical normal values are given in parentheses. In fact, in the normal brain, variations in vascular tone maintain a constant CBF across a range of MAP between 50 and 150 mmHg (or higher in the setting of chronic hypertension) and a corresponding range of CPP – the process of **cerebral autoregulation**. Autoregulation can be impaired in the context of trauma, so that MAP and ICP must be actively regulated in these patients to maintain proper perfusion.

The Monro-Kellie doctrine and herniation syndromes

Alexander Monro observed in 1783 that the cranium is a 'rigid box' containing a 'nearly incompressible brain'. Any expansion in the contents, especially haematoma and brain swelling, may be initially accommodated by exclusion of fluid components, venous blood and cerebrospinal fluid (CSF). Further expansion is associated with an exponential rise in ICP (***Figure 28.1***).

Uncontrolled increases in ICP result in cerebral herniation (***Figure 28.2***). Typically, herniation of the uncus of the temporal lobe over the tentorium results in pupil abnormalities (see ***Pupils***), usually occurring first on the side of any expanding haematoma. Cerebellar tonsillar herniation through the foramen magnum compresses medullary vasomotor and

†The learning objectives of this chapter are aligned with the Intercollegiate Surgical Curriculum Programme (ISCP) ST3 Neurosurgery Knowledge Requirements in Cranial Trauma and comprise:

- the resuscitation, assessment, investigation and continuing care of head-injured patients
- the prevention and detection of secondary intracranial and systemic insults.

Alexander Monro (secundus), 1733–1817, Scottish anatomist, physician and medical educator.
George Kellie, 1770–1829, Scottish surgeon and pupil of Alexander Monro (secundus).

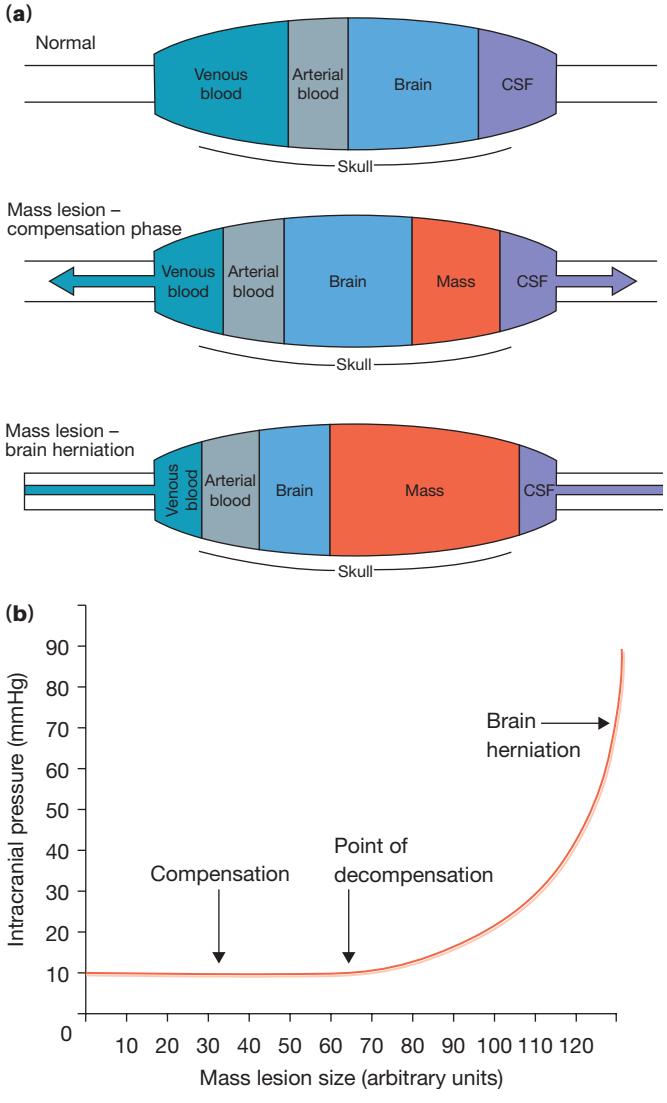

Figure 28.1 The Monro–Kellie doctrine accounts for the ability of the intracranial compartment to accommodate expanding mass lesions, primarily by excluding venous blood and cerebrospinal fluid (CSF), and the rapid rise in pressure associated with exhaustion of this compensation.

respiratory centres, classically producing **Cushing's triad**: hypertension, bradycardia and irregular respiration. The patient is then said to be '**coning**', and brainstem death will result without immediate intervention.

Summary box 28.1

Intracranial pressure

- A continuous supply of oxygenated blood is essential for brain survival
- Raised ICP can compromise cerebral perfusion, resulting in a cycle of secondary brain injury and swelling

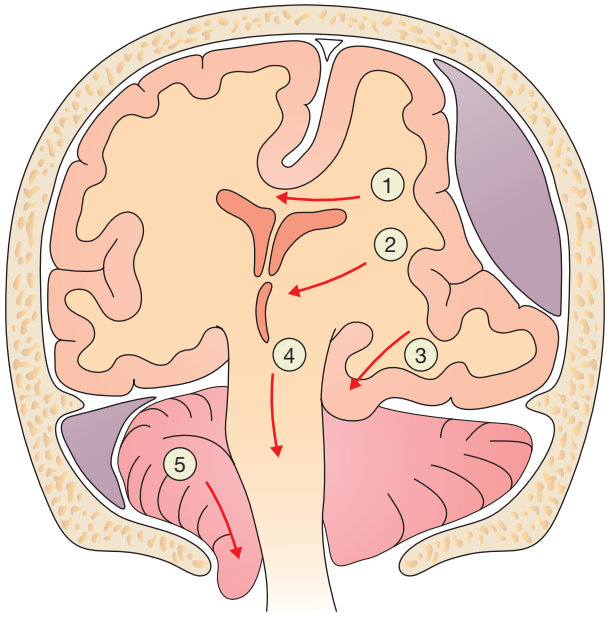

Figure 28.2 Brain herniation. (1) Subfalcine herniation – the cingulate gyrus is herniating under the falx cerebri. (2) Midline shift is evident. (3) Uncal herniation – the temporal lobe is herniating over the tentorium cerebelli, where it can compress the third nerve. (4) Central herniation and (5) tonsillar herniation result in brainstem compromise, manifesting as Cushing's triad.

CLASSIFICATION OF HEAD INJURY

The severity of head injury is classified according to the post-resuscitation Glasgow Coma Scale (GCS) score (*Table 28.1*), as it is the GCS score – and in particular the motor score – that is the best predictor of neurological outcome. In broad terms, significantly obtunded patients have moderate injuries and comatose patients have severe injuries; alcohol and drug effects often complicate the classification.

TABLE 28.1 Head injury severity: clinical classification.

Minor head injury	GCS 15 with no LOC
Mild head injury	GCS 14 or 15 with LOC
Moderate head injury	GCS 9–13
Severe head injury	GCS 3–8

GCS, Glasgow Coma Scale; LOC, loss of consciousness.

MINOR AND MILD HEAD INJURY

After exclusion of associated cervical spine injury, it is important to consider the possibility of a 'lucid interval' that may precede delayed deterioration due to an expanding intracranial haematoma. In general, patients with isolated head injuries and without ongoing deficits can be safely discharged from the emergency department, provided they meet suitable criteria,

Harvey Williams Cushing, 1869–1939, Professor of Surgery, Harvard University Medical School, Boston, MA, USA, considered the founding father of modern neurosurgery.

for instance those provided by the UK National Institute for Health and Care Excellence (NICE) (*Table 28.2*).

TABLE 28.2 UK National Institute for Health and Care Excellence discharge criteria in minor and mild head injury.

- GCS 15/15 with no focal deficits
- Normal CT brain if indicated (see *Table 28.3*)
- Patient not under the influence of alcohol or drugs
- Patient accompanied by a responsible adult
- Verbal and written head injury advice: seek medical attention if:
  - Persistent/worsening headache despite analgesia
  - Persistent vomiting
  - Drowsiness
  - Visual disturbance
  - Limb weakness or numbness

CT, computed tomography; GCS, Glasgow Coma Scale score.

Patients who do not meet all the discharge criteria will need admission for a further period of observation and/or brain imaging. Early computed tomography (CT) imaging is desirable in patients with a persistent reduced conscious level, focal deficits, suspected fractures or risk factors for intracranial bleed (*Table 28.3*). Significant clinical or radiological abnormalities should be discussed with the neurosurgical service. Many of these patients will struggle with features of concussion for a period after their injury, with headaches and somnolence typical. Follow-up by a head injury specialist nurse or equivalent is therefore desirable.

TABLE 28.3 UK National Institute for Health and Care Excellence (NICE) guidelines for computed tomography (CT) in head injury.

Indications for CT imaging in head injury within 1 hour
• GCS <13 at any point
• GCS <15 at 2 hours
• Focal neurological deficit
• Suspected open, depressed or basal skull fracture
• More than one episode of vomiting
• Post-traumatic seizure
Indications for CT imaging within 8 hours
• Age >65
• Coagulopathy (e.g. aspirin, warfarin or rivaroxaban use)
• Dangerous mechanism of injury (e.g. fall from a height, RTA)
• Retrograde amnesia >30 minutes

GCS, Glasgow Coma Scale score; RTA, road traffic accident.

Non-accidental injury

Head injury in children and vulnerable adults may be due to abuse. Significant findings include delayed presentation, injuries of disparate age, retinal haemorrhages, bilateral chronic subdural haematomas, multiple skull fractures and neurological injury without external signs of trauma.

Concussion, second impact syndrome and postconcussive syndrome

Concussion is defined as the alteration of consciousness as a result of closed head injury but is generally used to describe mild head injury without imaging abnormalities: loss of consciousness at the time of injury is not a prerequisite. Key features include confusion and amnesia. The patient may be lethargic, easily distractable, forgetful, slow to interact or emotionally labile. Gait disturbance and incoordination may be seen. While symptomatic following a head injury, patients may exhibit disordered cerebral autoregulation, making them especially vulnerable to repeat impacts. Second impact syndrome following an apparently trivial repeat injury comprises malignant brain swelling that can quickly progress to coma and death. Although the existence of the syndrome is disputed, and it is certainly rare, it should be considered in advice to individuals engaged in sports or activities carrying a risk of further injury: symptomatic players should not return to play.

Postconcussive syndrome is a loosely defined constellation of symptoms persisting for a prolonged period after injury. Patients may report somatic features such as headache, dizziness and disorders of hearing and vision. They may also suffer a variety of neurocognitive and neuropsychological disturbances, including difficulty with concentration and recall, insomnia, emotional lability, fatigue, depression and personality change. Some patients may exaggerate symptoms, seeking secondary gain (compensation).

Summary box 28.2

Minor and mild head injury

- Decisions on imaging and discharge are best made guided by published criteria
- In preverbal children and other vulnerable groups, non-accidental injury must be considered
- Amnesia, confusion, headaches and somnolence are typical features of concussion

MODERATE AND SEVERE TRAUMATIC BRAIN INJURY

Resuscitation and evaluation

Resuscitation is performed according to Advanced Trauma Life Support (ATLS) guidelines, beginning with management of the airway with cervical spine control and proceeding to assess and manage breathing and circulation. The history obtained in parallel is key to shaping ongoing management.

History

Mechanism

In moderate and severe TBI, a history must be obtained from witnesses and paramedics. High-energy mechanisms of injury, including a fall from a height or a high-speed road accident, will require careful clinical and radiological exclusion of associated multisystem and spinal injury (see *Chapters 27 and 30*). In the case of road traffic accidents in particular, extraction time and evidence of hypoxia or haemodynamic instability at the scene is important information to obtain from the paramedics. Falls

and crashes are often caused by a primary medical problem such as myocardial infarction, hypoglycaemia or subarachnoid haemorrhage, with crucial implications for management.

Neurological progression

A specific check should be made for any loss of consciousness at the time of injury and its duration. The GCS score and pupil responses should be recorded at the scene, during transfer, at admission and regularly thereafter. A deterioration in the GCS score is an important index of developing a potentially reversible secondary injury. It is also useful to assess the extent of amnesia, retrograde (events prior to the injury) and anterograde (events afterwards). If the patient was intubated at the scene of the accident, it is valuable to know whether the patient was moving all four limbs before this.

Past medical history

Obtain details of the patient's medical background, including allergies and normal medications. Of particular note here are antiplatelet agents, potentially requiring platelet transfusion especially if surgery is required, and anticoagulants, which may need reversal.

Summary box 28.3

History

- Bystanders and paramedics may give vital information on the:
  - Preinjury state (fits, alcohol, chest pain)
  - Mechanism and energy involved in the injury (speed of vehicles, height fallen)
  - Conscious state and haemodynamic stability of the patient after the accident
  - Length of time taken for extrication
- Check the medication history, especially anticoagulants and antiplatelet agents

Examination: primary survey

ATLS guidelines address a fundamental priority: ensuring uninterrupted perfusion of the brain with oxygenated blood. This is especially important after a head injury, given the disturbance to intracranial autoregulation and the sensitivity of the primary injured brain tissue to further insult. Bleeding from scalp lacerations may require management as part of the primary survey as the blood loss can be substantial and ongoing. Check the responsiveness of the pupils and conscious level and check for any gross focal neurological deficits. The blood glucose level should also be measured as early as possible as hypoglycaemia is very dangerous and easily reversible.

Pupils

The pupil size should be recorded in millimetres and the reactivity documented as present, sluggish or absent. Uncal herniation (*Figure 28.2*) can compress the third nerve, compromising the parasympathetic supply to the pupil. Unopposed sympathetic activity produces a sluggish enlarged pupil, progressing to fixed and dilated under continued compression. Established pupil changes may reflect pathology anywhere in the eye or the reflex loop made up by the optic nerve, the oculomotor nerve and the brainstem. Direct ocular trauma or nerve injury in association with a skull base fracture can cause mydriasis (dilated pupil) to be present from the time of injury. Pre-existing discrepancy in the pupil size (anisocoria), as a result of Holmes–Adie pupil or cataracts for example, may also complicate assessment.

Glasgow Coma Scale score

The GCS score is the sum of scores on three components, as detailed in *Table 28.4*. The breakdown of the GCS score into eye opening, verbal and motor components should always be recorded and used when communicating the status to other doctors. Remember that the score represents the best performance elicited, so a patient flexing in response to a painful stimulus on the left and localising on the right scores 'M5'. A sternal or supraorbital rub or trapezius squeeze represents an appropriate painful stimulus.

Neurological deficit

Gross focal neurological deficits, such as paraplegia, may be evident at the primary survey, and an assessment to exclude such a deficit should be carried out, especially if the patient is to be intubated so that subsequent examination will be impossible. Detailed neurological examination is included in the secondary survey.

TABLE 28.4 Glasgow Coma Scale score for head injury.

Eyes open	Spontaneously	4
	To verbal command	3
	To painful stimulus	2
	Do not open	1
Verbal	Normal	5
	Confused	4
	Inappropriate/words only	3
	Sounds only	2
	No sounds	1
	Intubated patient	T
Motor	Obeys commands	6
	Localises to pain	5
	Withdrawal/flexion	4
	Abnormal flexion	3
	Extension	2
	No motor response	1

Sir Gordon Morgon Holmes, 1876–1965, physician, National Hospital for Nervous Diseases, London, UK.
William John Adie, 1886–1935, physician, National Hospital for Nervous Diseases, London, UK.

Summary box 28.4

Primary survey

- Ensure adequate oxygenation and circulation
- Exclude hypoglycaemia
- Check pupil size and response and GCS score as soon as possible
- Check for focal neurological deficits before intubation if possible

Examination: secondary survey

A full secondary survey will be required. Particular attention must be paid to the head, neck and spine.

Head

Examination of the head should include inspection and palpation of the scalp for evidence of subgaleal haematoma and scalp lacerations, which may bleed profusely and potentially overlie fractures. Examine the face for evidence of fractures, especially to the orbital rim, zygoma and maxilla. Clinical evidence of a skull base fracture may include Battle's sign (*Figure 28.3*) and 'racoon' or 'panda' eyes (bilateral periorbital bruising). Haemotympanum, or overt bleeding from the ear if the tympanic membrane has ruptured, and CSF rhinorrhoea or otorrhoea are also highly suggestive of a fracture of the base of the skull.

A complete examination of the cranial nerves will reveal, for example, facial or vestibulocochlear nerve damage associated with skull base fracture. Midbrain or brainstem dysfunction may produce gaze paresis (inability of the eye to look across beyond the midline), dysconjugate gaze (inability of the eyes to work together) or roving eye movements. Inspect the conjunctiva and cornea of the eyes, and the retina using an ophthalmoscope, looking for hyphaema (blood in the anterior chamber of the eye), papilloedema or retinal detachment. Blood in the mouth may be due to tongue-biting at seizure. The GCS score and pupil status, assessed as part of the primary survey, require re-evaluation at the secondary survey and regularly thereafter.

Figure 28.3 Battle's sign. A skull base fracture may be associated with bruising over the mastoid process.

Neck and spine

Studies have demonstrated an incidence of cervical fracture of up to 10% in association with moderate and severe TBI. Cervical spine injury must be presumed in the context of head injury until actively excluded. In a high-energy mechanism such as a road traffic accident or fall from a height, thoracic and lumbar spine injuries must also be excluded. Plain radiographs are of limited value in excluding significant cervical spine injury. Even CT imaging does not exclude the possibility of significant ligamentous injury. Therefore, whenever feasible, these patients should be managed in a hard collar until the neck can be cleared clinically.

A peripheral nerve examination with documentation of limb tone, power, reflexes and sensation needs to be performed early to identify spinal pathology. This is especially important in patients who may subsequently be intubated and ventilated when this assessment will no longer be possible. Obtunded patients should move all four limbs in response to an appropriate painful stimulus.

The patient will need to be log-rolled to palpate for thoracic or lumbar deformity, and any cervical collar should be removed at this stage to allow palpation of the cervical spine before it is then replaced again. If there is associated spinal injury, a thoracic sensory level is much more easily established by sensory examination on the back. A per rectum examination is also performed at log-roll, assessing for anal tone, sensation in the awake patient and anal wink (sphincter seen to contract in response to a pinprick stimulus). Priapism is a strong predictor of severe cord injury even in intubated patients.

Summary box 28.5

Secondary survey

- Battle's sign, periorbital bruising and blood in the ears/nose/mouth may point to a base of skull fracture
- Cervical spine fractures are common and must be actively excluded
- Log-roll to check the whole spine for steps and tenderness and for a per rectum examination

Surgical pathology

Fractures: skull vault

Closed linear fractures of the skull vault are managed conservatively. Open or comminuted fractures should be considered for

William Henry Battle, 1855–1936, surgeon, St Thomas's Hospital, London, UK.

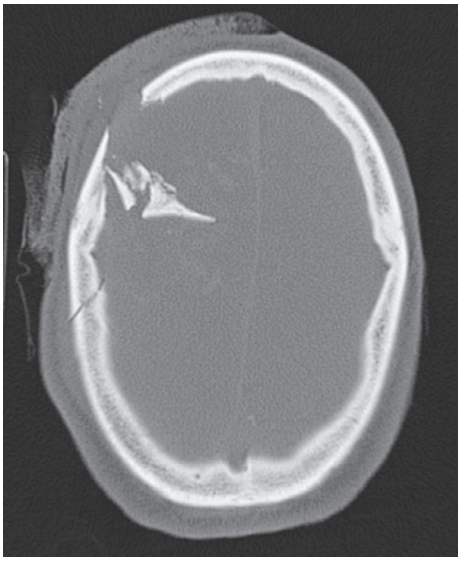

Figure 28.4 A right frontal comminuted depressed skull fracture, with a linear undisplaced fracture of the right parietal bone visible posteriorly.

debridement and prophylactic antibiotic therapy. Depressed skull fractures involve inward displacement of a bone fragment by at least the thickness of the skull (***Figures 28.4 and 28.5***). They occur when small objects hit the skull at high velocity. They are usually compound (open) fractures, and are associated with a high incidence of infection, neurological deficit and late-onset epilepsy. These fractures require exploration and elevation, especially where intracranial air is present, pointing to a breach in the dura mater. Fractures that involve the air sinuses should generally be managed as open fractures, using broad-spectrum antibiotics with or without exploration.

Fractures: skull base

Clinical signs of skull base fracture include bleeding or CSF leak from the ears (otorrhoea) or nose (rhinorrhoea) and bruising behind the ear (***Figure 28.3***) or around the eyes. Skull base fractures may be complicated by pituitary dysfunction, arterial dissection or cranial nerve deficits, with anosmia, facial palsy or hearing loss typical. CSF leak will generally resolve spontaneously but persistent leak can result in meningitis so repair may be required. Blind nasogastric tube placement is contraindicated in these patients.

Extradural haematoma

Extradural haematoma (***Figure 28.6***) is a neurosurgical emergency. It results from rupture of an artery, vein or venous sinus, in association with a skull fracture. The classical injury is a fracture to the thin squamous temporal bone, with associated damage to the middle meningeal artery. Transient loss of consciousness is typical, and the patient may then present in the subsequent lucid interval with headache but without any neurological deficit. As the haematoma expands, compensation is exhausted (see ***The Monro–Kellie doctrine and herniation syndromes***) with rapid deterioration. There is contralateral hemiparesis, a reduced conscious level and ipsilateral pupillary

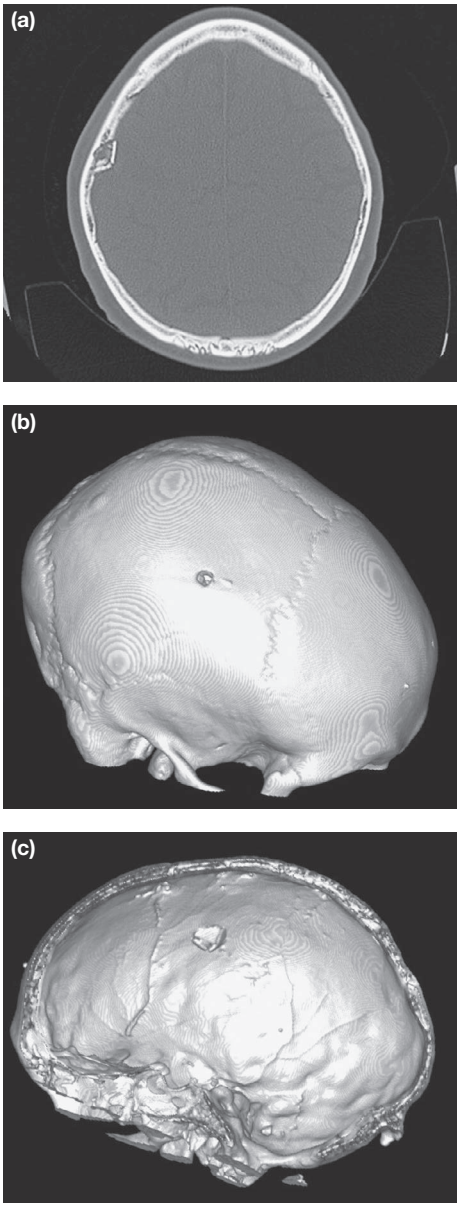

Figure 28.5 (a–c) A small depressed skull fracture of the parietal bone visible on an axial bone window **(a)**, visualised on bone vault reconstructions **(b)** with an underlying breach of the dura **(c)**.

dilatation, the cardinal signs of brain compression and herniation. Although this '**talk and die**' pattern of deterioration occurs in only one-third of cases, it is critically important to recognise the potential for rapid avoidable secondary brain injury in patients who present neurologically intact.

On CT, extradural haematomas appear as a lentiform (lens-shaped or biconvex) hyperdense lesion between the skull and the brain, constrained by the adherence of the dura to the skull. A mass effect may be evident, with compression of the surrounding brain and midline shift. Areas of mixed density suggest active bleeding. A skull fracture will usually be evident. Significant extradural haematoma mandates urgent transfer to the most accessible neurosurgical facility for immediate evacuation in deteriorating or comatose patients or those with large bleeds and for close observation with serial imaging in

other cases. The prognosis for promptly evacuated extradural haematoma, without associated primary brain injury, is excellent.

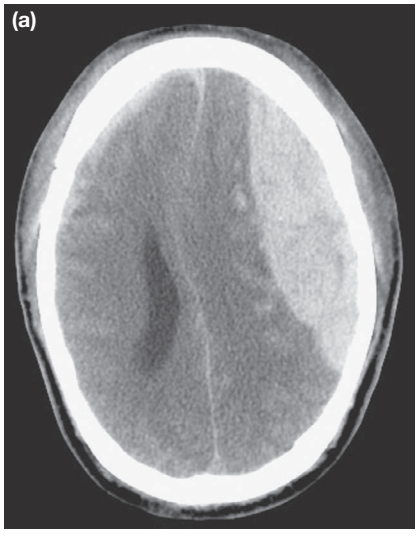

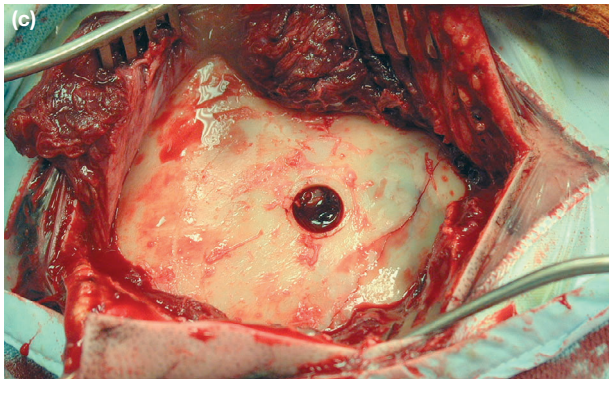

Figure 28.6 (a) A large left extradural haematoma (note the biconvex shape) exerts a mass effect; a smaller right acute subdural haematoma is also evident. **(b)** Right frontal intracerebral haematoma extending into the lateral ventricle is evident. There is a small right posterior extradural haematoma and traumatic subarachnoid bleeding in the sulci of the right hemisphere. **(c)** A surgical temporal bone exposure showing a linear skull fracture with underlying extradural haematoma visible through a burr hole.

Summary box 28.6

Extradural haemorrhage

- Can follow relatively minor trauma with brief loss of consciousness
- Followed by a lucid interval and then sudden deterioration
- Lentiform lesion on CT
- Require immediate transfer to a neurosurgical unit for decision on evacuation

Acute subdural haematoma

Acute subdural haematoma (*Figure 28.7*) is encountered in two broadly distinct contexts. First, high-energy injury mechanisms can result in the rupture of cortical surface vessels with significant associated primary brain injury. This results in an expanding haematoma with rapid deterioration and

Figure 28.7 (a) Right-sided acute subdural haematoma (hyperdense). The substantial midline shift reflects brain swelling as well as bleeding – this is a high-energy injury. **(b)** Bilateral subdural haematomas: the left is mixed density, the hypodense material representing old blood and the higher density indicating more recent bleeding, probably loculated so requiring a craniotomy to evacuate. The bleed on the right is isodense, indicating intermediate age.

development of signs of raised ICP reminiscent of extradural haematoma, without the lucid interval. These collections require prompt evacuation, typically by craniotomy or craniectomy.

In a second group of patients, older and often anticoagulated, a lower energy injury leads to venous bleeding around the brain. Depending on the total volume of bleeding, the resulting haematoma may present early as acute subdural haematoma, after delay and osmotic expansion as chronic subdural haematoma or may even remain clinically silent. This last group may present much later with a further 'acute-on-chronic' subdural haematoma. On diagnosis, clotting function should be corrected wherever possible. Bleeds of significant size, with significant associated midline shift or with deteriorating neurology, require urgent evacuation. Smaller bleeds in neurologically stable patients may be managed conservatively, at least initially: liquefaction of the clot over 7–10 days after the bleed may allow for a much less invasive evacuation through burr holes.

Since the dura is not as adherent to the brain as it is to the skull, subdural blood is free to expand across the brain surface, giving a diffuse concave appearance.

Summary box 28.7

Acute subdural haemorrhage

- High-energy injuries, or elderly/anticoagulated
- Generally require urgent evacuation by craniotomy/craniectomy

Chronic subdural haematoma

Chronic subdural haematoma (*Figure 28.7*) is a common cause of acute neurological deterioration in older adults. Cerebral atrophy in this age group results in stretching of the cortical–dural bridging veins, which are then vulnerable to rupture. The resulting haematoma can expand over days or weeks by osmosis, ultimately producing symptoms of raised ICP or focal deficits. There is usually a history of recent injury, but, especially in the context of antiplatelet or anticoagulant medication, even apparently trivial impacts may be responsible.

On presentation it is important to exclude coexisting electrolyte disturbance and infections, which may contribute to clinical impairment. Imaging reveals diffuse hypodensity overlying the brain surface. Recent bleeding may be isodense or hyperdense, and mixed density can indicate an acute-on-chronic subdural haematoma.

Anticoagulation should be reversed, either by administration of vitamin K or urgently by transfusion of recombinant clotting factors in patients who have deteriorated acutely. Conservative management, sometimes with administration of corticosteroids, can be considered for small bleeds without symptoms or with headache alone. For the majority drainage is performed using burr holes. Urgency is dictated by the clinical condition of the patient and imaging evidence of mass effect. If clinically stable, a delay of 7–10 days to allow platelet function to normalise after withdrawal of aspirin/clopidogrel may be considered.

Summary box 28.8

Chronic subdural haemorrhage

- Common in the elderly, especially those on anticoagulants
- Clinical deficits result from osmotic expansion of a degrading clot over days/weeks
- Diffuse hypodense lesion on CT
- Burr hole drainage is usually preferred

Traumatic subarachnoid haemorrhage

Trauma is the commonest cause of subarachnoid haemorrhage (*Figures 28.6b and 28.8*), and this is managed conservatively. It is not usually associated with significant vasospasm, which characterises aneurysmal subarachnoid haemorrhage. The possibility of spontaneous subarachnoid haemorrhage actually leading to collapse and so causing a head injury needs to be borne in mind, and formal or CT angiography may be required to exclude this.

Cerebral contusions

Contusions are common and are found predominantly where the brain is in contact with the irregularly ridged inside of the skull, i.e. at the inferior frontal lobes and temporal poles. '**Coup contre-coup**' contusions refer to brain injury both at the site of impact and distant to this, where the brain impacts on the inside of the skull as the skull and brain accelerate and then decelerate out of synchrony with each other. Contusions appear heterogeneous on CT, reflecting their composition of injured brain matter interspersed with acute blood (*Figure 28.8*). Contusions rarely require surgical intervention but may warrant delayed evacuation to reduce a mass effect.

Figure 28.8 A large right extradural haematoma is evident. There are widespread cerebral contusions most prominent in the left frontal lobe. There is traumatic subarachnoid blood in the third and lateral ventricles.

Diffuse axonal injury

This is a form of primary brain injury seen in high-energy accidents that usually renders the patient comatose; it is associated with poor outcomes. It is strictly a pathological diagnosis made at postmortem, but haemorrhagic foci in the corpus callosum and dorsolateral rostral brainstem on CT may be suggestive. Magnetic resonance imaging is more sensitive and is employed to evaluate for diffuse axonal injury in patients who fail to improve neurologically.

Arterial dissection

Cerebral arterial dissection occurs spontaneously or in the context of trauma. In the hours after significant trauma, dissection of the carotid extracranially, or at the skull base in association with fractures, is most common. It presents with headache, neck pain and focal ischaemic deficits due to occlusion by mural haematoma, thrombus and thromboembolism. Intracranial dissection often affects the vertebral artery and may result in subarachnoid bleeding.

Summary box 28.9

Specific injuries

- Traumatic versus primary subarachnoid haemorrhage is an important distinction
- Cerebral contusions arise adjacent to rough bone surfaces
- Diffuse axonal injury results from extreme accelerations of the skull contents
- Arterial dissection is associated with fractures of the skull base

Medical management

From initial resuscitation, through surgical intervention and into the subsequent phase of ICU management, medical management strategies aim to minimise secondary brain injury through avoidance of hypoxia and hypotension and control of ICP. Unchecked, secondary injury leads to a further cycle of deterioration (*Figures 28.2 and 28.9*).

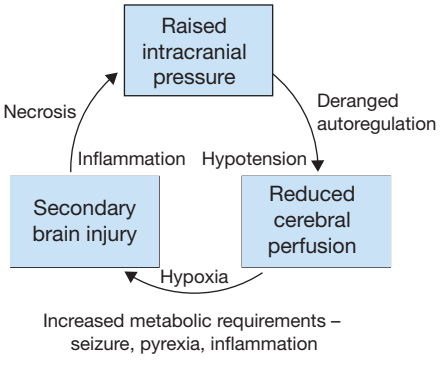

Figure 28.9 Brain swelling and mass lesions contribute to raised intracranial pressure, which compromises perfusion, leading to secondary brain injury and further swelling.

The role of neurosurgical centres

Early discussion of patients and imaging with the regional neurosurgical service is advisable. UK trauma audit and research network data show higher mortality in patients with severe TBI managed in non-neurosurgical centres, and this is reflected in NICE guidelines, which recommend early transfer irrespective of the need for surgery.

Control of intracranial pressure

Intubation and ventilation are required early in the management of severe brain injury for airway control. They are often required in moderate brain injury to facilitate the safe management and transfer of unstable and frequently agitated patients and in order to control ICP. A bolus of mannitol or hypertonic saline may be administered to temporise ICP, for example while scanning and transferring the patient.

Management of the intubated patient, following evacuation of any focal haematomas, is guided by ICP monitoring using a bolt ICP monitor or else an external ventricular drain inserted into the lateral ventricle, which can also contribute to ICP control by permitting CSF drainage. A sustained elevated ICP exceeding 20–25 mmHg is associated with a poor outcome, and maintenance of a CPP of at least 60 mmHg is important in preventing secondary injury.

ICP can be controlled by simple measures, including raising the head of the bed and loosening the collar to improve venous drainage. Seizures and pyrexia should be actively controlled. Medical management titrated to ICP includes escalating doses of sedatives, analgesics and ultimately muscle relaxants. Target ventilatory and circulatory parameters are set out in *Table 28.5*.

TABLE 28.5 Key parameters to maintain in head-injured patients in neurointensive care.

- $PaCO_2$ = 4.5–5.0 kPa
- PaO_2 >11 kPa
- MAP = 80–90 mmHg
- ICP <20 mmHg
- CPP >60 mmHg
- $[Na^+]$ >140 mmol/L
- $[K^+]$ >4 mmol/L

$[K^+]$, plasma potassium concentration; $[Na^+]$, plasma sodium concentration; CPP, cerebral perfusion pressure; ICP, intracranial pressure; MAP, mean arterial pressure; $PaCO_2$, partial pressure of carbon dioxide in arterial blood; PaO_2, partial pressure of oxygen in arterial blood.

Where these measures fail, neurointensivists may seek to control brain swelling using mannitol or hypertonic saline infusions. Where autoregulation is preserved, inducing high CPP may reduce ICP through vasoconstriction. A range of further interventions are effective in controlling ICP, but evidence for long-term outcome benefit is limited or absent. These interventions include induction of therapeutic hypothermia or thiopentone coma and surgical decompressive craniectomy.

Pituitary dysfunction

Electrolyte imbalance is common in TBI and contributes to brain swelling and to causing seizures. Diverse mechanisms

are involved. Cerebral salt wasting, a poorly understood form of excretory dysregulation in association with brain insult, leads to volume depletion and hyponatraemia. The syndrome of inappropriate antidiuretic hormone (SIADH) leads to water retention and hyponatraemia in the context of pituitary damage. This is of particular concern in head injury since low serum osmotic pressure can contribute to brain swelling, so hypotonic fluids are avoided in this setting. Conversely antidiuretic hormone secretion may be compromised in the context of trauma, producing diabetes insipidus, resulting in hypernatraemia.

All aspects of pituitary function may be compromised in the setting of TBI. Routine screening of pituitary hormone levels and liaison with endocrinology are important aspects of optimal medical management. Note that routine, rather than directed, administration of corticosteroids in severe head injury is associated with increased mortality and is not recommended.

Seizures

Seizures may occur early (within 7 days) or late. The cumulative probability is between 2% (mild TBI) and 60% (severe TBI with exacerbating features). Risk factors include injury severity, especially the presence of intracerebral haemorrhage, depressed skull fractures and tears of the dura. Antiepileptics, typically phenytoin, are administered prophylactically to patients at high risk of seizures.

Nutrition

Enteral nutrition is preferred to intravenous parenteral nutrition on the grounds of cost and associated complications, and should be commenced within 72 hours of injury. Prokinetics (e.g. metoclopramide, erythromycin) can be administered to promote absorption.

Outcomes and sequelae

The long-term sequelae of moderate and severe TBI include headache and memory and cognitive impairments, contributing to the postconcussive syndrome described above. Rehabilitation represents a complex and prolonged multidisciplinary challenge. The Glasgow Outcome Scale score is used to quantify the degree of recovery achieved after head injury, especially for research purposes, and is detailed in *Table 28.6*. Good recovery implies independence and potential to return to work rather than a full return to previous capacity.

TABLE 28.6 Glasgow Outcome Scale.

Good recovery	5
Moderate disability	4
Severe disability	3
Persistent vegetative state	2
Dead	1

Summary box 28.10

Medical management of head injury

- First line ICP control involves optimising sedation, ventilation and serum sodium levels
- Paralysis and external ventricular CSF drainage are important adjuncts
- There is little evidence for benefit with therapeutic hypothermia, barbiturate coma or decompressive craniectomy
- Check pituitary function, consider seizure prophylaxis, commence enteral nutrition within 72 hours

TRAUMATIC BRAIN INJURY IN THE CHILD

Head injury in children is common and presents specific challenges relating to physiology, assessment, management and safeguarding. Children have large heads compared with the rest of their bodies, predisposing to both head and neck injury. In the case of minor head injury, good assessment depends on winning the trust of child and parent, while identifying risk factors requiring further admission for observation or CT scan (*Table 28.7*). Non-accidental injury should always be considered; for example, it is key to ensure that the reported mechanism of injury is in keeping with the child's developmental stage and to examine for injuries outside the normal distribution for childhood accidents. The Paediatric Glasgow Coma Scale is applied in the under-twos (*Table 28.8*).

Moderate and severe head injury should be managed by a trauma team in a resuscitation room, using paediatric ATLS protocols directed at optimising physiology to prevent secondary brain injury, and with intensive care unit (ICU) involvement for airway management as appropriate. Children with open sutures can lose substantial blood volumes into the head. Palpating the fontanelle allows direct assessment of ICP, and in all cases head and neck CT imaging are key to guiding definitive management.

TABLE 28.7 UK National Institute for Health and Care Excellence criteria for computed tomography scan in children following head injury.

- Suspicion of NAI
- First seizure
- GCS <14 or <15 in under-ones
- GCS <15 2 hours post injury
- Signs of fracture of the base of skull
- Focal neurological deficit
- Bruise/swelling/laceration >5 cm in under-ones
- More than one of:
  - Loss of consciousness >5 minutes
  - Abnormal drowsiness
  - Four or more episodes of vomiting
  - Dangerous mechanism
  - Amnesia >5 minutes

GCS, Glasgow Coma Scale score; NAI, non-accidental injury.

TABLE 28.8 Paediatric Glasgow Coma Scale score.

Eye opening	Spontaneously	4
	To verbal stimulus	3
	To pain	2
	No response	1
Verbal response	Coos/babbles	5
	Irritable cries	4
	Cries in response to pain	3
	Moans in response to pain	2
	No response	1
Motor response	Purposeful/spontaneous movements	6
	Withdraws to touch	5
	Withdraws to pain	4
	Flexes to pain	3
	Extends to pain	2
	No response	1

FURTHER READING

Greenberg MS. *Handbook of neurosurgery*, 9th edn. Stuttgart: Thieme Medical Publishers, 2019.

Samandouras G (ed.). *The neurosurgeon's handbook*. Oxford: Oxford University Press, 2010.